

## REVIEW ARTICLE

Dan L. Longo, M.D., *Editor*

## Drug-Induced Liver Injury — Types and Phenotypes

Jay H. Hoofnagle, M.D., and Einar S. Björnsson, M.D.

From the Liver Disease Research Branch, Division of Digestive Diseases and Nutrition, National Institute of Diabetes and Digestive and Kidney Diseases, National Institutes of Health, Bethesda, MD (J.H.H.); and the Department of Internal Medicine, National University Hospital of Iceland, and the Faculty of Medicine, University of Iceland — both in Reykjavík (E.S.B.). Address reprint requests to Dr. Hoofnagle at the Liver Disease Research Branch, Rm. 6005, Democracy II, 6707 Democracy Blvd., Bethesda, MD 20892, or at hoofnaglej@nih.gov.

N Engl J Med 2019;381:264-73.

DOI: 10.1056/NEJMra1816149

Copyright © 2019 Massachusetts Medical Society.

**D**RUG-INDUCED LIVER INJURY IS AN UNCOMMON BUT CHALLENGING clinical problem with respect to both diagnosis and management.<sup>1-3</sup> Its incidence is estimated to be 14 to 19 cases per 100,000 persons, with jaundice accompanying 30% of cases.<sup>4,5</sup> Drug-induced liver injury is responsible for 3 to 5% of hospital admissions for jaundice<sup>6</sup> and is the most frequent cause of acute liver failure in most Western countries, accounting for more than half of cases.<sup>7,8</sup> Advances have been made in our understanding of viral, autoimmune, and genetic liver diseases, as well as approaches to their prevention and treatment, but progress on these fronts has been modest in the case of drug-induced liver injury.

The diagnosis of drug-induced liver injury is particularly challenging, since it is based largely on exclusion of other causes. The timing of the onset of injury after the implicated agent has been started (latency), resolution after the agent is stopped (“dechallenge”), recurrence on re-exposure (rechallenge), knowledge of the agent’s potential for hepatotoxicity (likelihood), and clinical features (phenotype) are the major diagnostic elements.<sup>9-11</sup> With few exceptions, there are no specific diagnostic markers for drug-induced liver injury, and special tests (liver biopsy, imaging, and testing for serologic markers) are helpful mostly in ruling out other causes of liver injury. The large number of agents that can cause liver injury highlights these challenges. LiverTox, the National Institutes of Health–sponsored website on hepatotoxicity, has descriptions of more than 1200 agents (prescription and over-the-counter medications, herbal products, nutritional supplements, metals, and toxins), along with their potential to cause liver injury.<sup>12</sup> Among the 971 prescription drugs described, 447 (46%) have been implicated in causing liver injury in at least one published case report.<sup>11</sup> This brief review cannot cover all aspects of drug-induced liver injury but focuses on general principles, newer concepts, and current challenges, with frequent references to the LiverTox website for further detail.

## TYPES OF DRUG-INDUCED LIVER INJURY

Drug-induced liver injury is typically classified as either direct or idiosyncratic,<sup>1</sup> but indirect injury is emerging as a third type (Table 1). Direct hepatotoxicity is caused by agents that are intrinsically toxic to the liver. The injury is common, predictable, dose-dependent, and reproducible in animal models.<sup>1</sup> The latency period is typically short, usually with an onset within 1 to 5 days after high therapeutic or supratherapeutic doses, as in the case of an intentional or accidental overdose.

Idiosyncratic hepatotoxicity is caused by agents that have little or no intrinsic toxicity and that cause liver injury only in rare cases, typically after 1 in 2000 to 1 in 100,000 patient-exposures.<sup>5,13</sup> The injury is unpredictable, not dose-dependent, and not reproducible in animal models. Idiosyncratic liver injury is categorized as hepatocellular, cholestatic, or both (mixed) on the basis of the R ratio, calculated by

**Table 1. Drug-Induced Liver Injury According to Type.\***

Variable	Direct Hepatotoxicity	Idiosyncratic Hepatotoxicity	Indirect Hepatotoxicity
Frequency	Common	Rare	Intermediate
Dose-related	Yes	No	No
Predictable	Yes	No	Partially
Reproducible in animal models	Yes	No	Not usually
Latency (time to onset)	Typically rapid (days)	Variable (days to years)	Delayed (months)
Phenotypes	Acute hepatic necrosis, serum enzyme elevations, sinusoidal obstruction, acute fatty liver, nodular regeneration	Acute hepatocellular hepatitis, mixed or cholestatic hepatitis, bland cholestasis, chronic hepatitis	Acute hepatitis, immune-mediated hepatitis, fatty liver, chronic hepatitis
Most commonly implicated agents	High doses of acetaminophen, niacin, aspirin, cocaine, IV amiodarone, IV methotrexate, cancer chemotherapy	Amoxicillin–clavulanate, cephalosporins, isoniazid, nitrofurantoin, minocycline, fluoroquinolones, macrolide antibiotics	Antineoplastic agents, glucocorticoids, monoclonal antibodies (against tumor necrosis factor, CD20, checkpoint proteins), protein kinase inhibitors
Cause	Intrinsic hepatotoxicity when agent given in high doses	Idiosyncratic metabolic or immunologic reaction	Indirect action of agent on liver or immune system

\* IV denotes intravenous.

dividing the alanine aminotransferase level by the alkaline phosphatase level from the time of initial presentation, with both values expressed as multiples of the upper limit of the normal range.<sup>9</sup> Hepatocellular injury is defined as an R value of more than 5, cholestatic injury as a value of less than 2, and mixed injury as a value of 2 to 5.

Indirect hepatotoxicity is caused by the action of the drug (what it does) rather than by its toxic or idiosyncratic properties (what it is). Indirect injury can represent induction of a new liver condition or an exacerbation of a preexisting condition, such as induction of immune-mediated hepatitis or worsening of hepatitis B or C or fatty liver disease.

#### MAJOR PHENOTYPES

The three types of drug-induced liver injury are manifested by distinctly different patterns of clinical features (phenotypes)<sup>12</sup> (Table 2).

#### DIRECT HEPATOXICITY

Serum enzyme elevations without jaundice constitute the most common pattern of direct drug-induced liver injury, with elevations of alanine aminotransferase or alkaline phosphatase levels but without hyperbilirubinemia and with minimal or no symptoms.<sup>2,12</sup> The elevations resolve when the drug is stopped or the dose is lowered but can also resolve spontaneously, a phenomenon referred to as adaptation.<sup>14</sup> In some cases,

adaptation does not occur, and enzyme elevations worsen and jaundice and symptoms arise. The mechanism or mechanisms underlying adaptation are unknown but may result from changes in drug-metabolizing enzyme activity, up-regulation of hepatoprotective pathways, or down-regulation of hypersensitivity reactions to the drug or its metabolites.

Acute hepatic necrosis is the most common form of clinically apparent direct hepatotoxicity. The injury occurs abruptly, soon after the medication has been started, often after exposure to a single high dose or a dose increase (Fig. 1A). Serum alanine aminotransferase levels rise to high values, whereas alkaline phosphatase levels are minimally elevated. In severe cases, signs of hepatic failure such as coagulopathy, hyperammonemia, or coma arise within days.<sup>7,19</sup> Liver histologic studies show centrilobular or panlobular necrosis with little inflammation, a pattern similar to that of ischemic hepatitis, the major disorder in the differential diagnosis. Acute hepatic necrosis can be fatal, but if it is not, recovery is rapid, and serum enzyme levels fall almost as rapidly as they rose. High doses of acetaminophen, aspirin, niacin, amiodarone, and many antineoplastic agents can cause acute hepatic necrosis.<sup>15,19,20</sup> Typically, these drugs can be restarted at lower doses without a recurrence of injury. Poisonous mushrooms (*Amanita phalloides*) and other environmental toxins can cause a similar syndrome of acute hepatic necrosis.

**Table 2. Phenotypes of Drug-Induced Liver Injury.\***

Phenotype	Type of Liver Injury	Latency	Enzyme Pattern	Typical Agents	Comments
Acute hepatic necrosis	Direct	Days	Marked, abrupt ALT elevations; mild Alk P and bilirubin elevations	Acetaminophen, aspirin, niacin, "Ecstasy"	Often due to overdose
Enzyme elevations	Direct	Days to months	Mild-to-moderate ALT or Alk P elevations	Many agents	Usually transient and asymptomatic
Acute hepatitis	Idiosyncratic, indirect	Days to months	High ALT elevations, modest Alk P elevations	Isoniazid, diclofenac	High death rate
Cholestatic hepatitis	Idiosyncratic	Weeks to months	High Alk P elevations, modest ALT elevations	Amoxicillin–clavulanate, cefazolin	Pruritus, early and prominent
Mixed hepatitis	Idiosyncratic	Days to months	Moderate ALT and Alk P elevations	TMP-SMZ, phenytoin	Usually benign, self-limited
Chronic hepatitis	Idiosyncratic, indirect	Months to years	Moderate ALT elevations with bilirubin elevations	Diclofenac, nitrofurantoin, minocycline	Insidious onset; may require glucocorticoids
Bland cholestasis	Unknown, possibly idiosyncratic	Months	Moderate ALT elevations, mild Alk P elevations	Anabolic steroids, estrogens	Pruritus, prominent and prolonged
Acute fatty liver, lactic acidosis, and hepatic failure	Direct	Days to months	Lactic acidosis, modest ALT elevations, hepatic failure	Stavudine, linezolid, aspirin (Reye's syndrome)	Mitochondrial failure, pancreatitis
Nonalcoholic fatty liver	Indirect, direct	Months	Mild ALT and Alk P elevations	Glucocorticoids, tamoxifen, haloperidol	Asymptomatic; fatty liver seen on ultrasound
Sinusoidal obstruction syndrome	Direct	Weeks	Variable enzyme elevations	Cancer agents, busulfan, gemtuzumab	Hepatomegaly, weight gain, edema, ascites
Nodular regenerative hyperplasia	Direct	Years	Minimal ALT and Alk P elevations	Thioguanine, azathioprine, oxaliplatin	Noncirrhotic portal hypertension

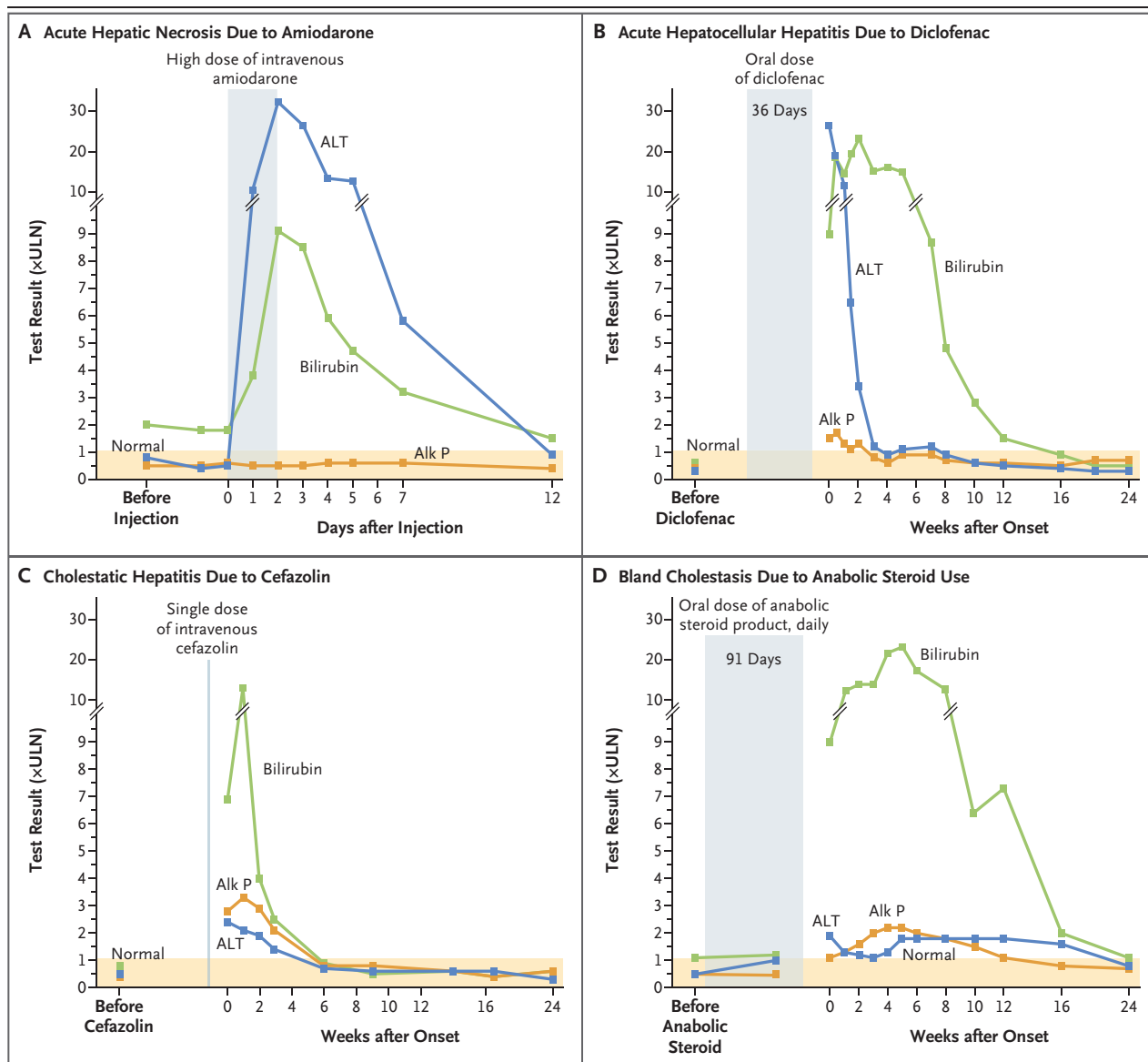
\* The phenotypes are listed very generally in order of frequency; there is some overlap between idiosyncratic and indirect forms of injury. Alk P denotes alkaline phosphatase, ALT alanine aminotransferase, and TMP-SMZ trimethoprim–sulfamethoxazole.

Sinusoidal obstruction syndrome, previously known as veno-occlusive disease, is due to acute injury and loss of intrasinusoidal endothelial cells, resulting in obstruction of sinusoidal blood flow and liver injury.<sup>21,22</sup> Drugs are the usual cause, the most common being myeloablative agents administered in preparation for hematopoietic cell transplantation. Symptoms of abdominal pain, increase in liver size, and weight gain, followed by jaundice, appear 1 to 3 weeks after exposure and may progress rapidly to hepatic failure. Liver histologic studies show dilatation of sinusoids and extravasation of red cells, with hepatocyte necrosis in central areas (zone 3).<sup>22</sup> Drugs that cause sinusoidal obstruction syndrome include alkylating agents such as busulfan or cyclophosphamide and monoclonal antibody–cytotoxic conjugates such as gemtuzumab ozogamicin.<sup>23</sup> The syndrome can also be caused by botanicals (pyrrolizidine alkaloids).<sup>1</sup> Defibrotide, an antithrombotic agent, has recently been approved as therapy for severe sinusoidal ob-

struction syndrome with organ failure, but its use is controversial.<sup>24</sup>

Nodular regenerative hyperplasia is usually manifested as unexplained, noncirrhotic portal hypertension with esophageal varices or ascites. Nodular regeneration can be caused by cancer chemotherapeutic agents given over a long period or in multiple courses (azathioprine, mercaptopurine, or thioguanine)<sup>25</sup> or by first-generation nucleoside antiretroviral agents (zidovudine, stavudine, or didanosine).<sup>26</sup> Nodular regenerative hyperplasia with resultant portal hypertension has also been linked to oxaliplatin infusions for metastatic colon cancer.<sup>27</sup> The pathogenesis of nodular regeneration is unclear, but it may be the result of chronic injury to the hepatic microvasculature. Management should include withdrawal of the medication (and avoidance of similar agents) and treatment of portal hypertension.

Lactic acidosis with microvesicular steatosis and hepatic dysfunction typically occurs with nonspecific symptoms of abdominal discomfort,



**Figure 1. Common Phenotypes of Drug-Induced Liver Injury.**

Panel A shows an example of acute hepatic necrosis and direct liver injury. A 48-year-old woman with valvular heart disease had marked alanine aminotransferase (ALT) elevations with jaundice but no increase in alkaline phosphatase (Alk P) levels, within a day after starting to receive intravenous amiodarone (300-mg bolus followed by 900 mg daily). The abnormalities reversed rapidly on withdrawal of the medication.<sup>15</sup> She later received oral amiodarone without recurrence of the liver injury. Panel B shows an example of idiosyncratic acute hepatocellular hepatitis. A 77-year-old woman presented with jaundice 36 days after starting diclofenac (75 mg twice daily) for osteoarthritis, with marked ALT but minimal Alk P elevations, profound jaundice, transient signs of liver failure, and subsequent spontaneous but slow resolution.<sup>16</sup> Panel C shows an example of idiosyncratic cholestatic hepatitis. Itching and jaundice developed in a 68-year-old man a week after he received a single intravenous infusion of cefazolin (1 g) during outpatient orthopedic surgery. He had prominent Alk P elevations but modest ALT elevations, which resolved within a few weeks after their onset.<sup>17</sup> Panel D shows an example of bland cholestasis. Jaundice developed in a 39-year-old man approximately 3 months after he started a bodybuilding regimen that included daily doses of an oral anabolic steroid, with modest ALT and Alk P elevations, despite marked and prolonged itching and hyperbilirubinemia.<sup>18</sup> For all four cases, the test results are given as multiples of the locally defined upper limit of the normal range (ULN), except in the case of bilirubin, for which the ULN was set at 1.0 mg per deciliter (17.1  $\mu$ mol per liter).

fatigue, and weakness, with subsequent confusion, stupor, and coma accompanied by liver injury.<sup>28</sup> Lactic acidosis or hyperammonemia may

be prominent. Jaundice arises late, and enzyme elevations are variable, sometimes markedly hepatocellular (with Reye's syndrome triggered by

aspirin)<sup>29</sup> and sometimes with milder, mixed patterns. The time to onset can be days (with aspirin or intravenous tetracycline),<sup>30</sup> weeks (with linezolid),<sup>31</sup> or months (with didanosine).<sup>28,32</sup> Liver biopsy shows microvesicular steatosis with minimal inflammation and necrosis. The pathogenesis of the injury is mitochondrial toxicity and failure of aerobic metabolism. Similar injury in other tissues may accompany and overshadow the liver injury (neuropathy, myopathy, and pancreatitis). Therapy should focus on withdrawal of the responsible agent, administration of glucose infusions, and correction of acidosis.<sup>28</sup>

#### IDIOSYNCRATIC HEPATOTOXICITY

Acute hepatocellular hepatitis is the most common manifestation of idiosyncratic liver injury.<sup>5,13,33</sup> The latency period generally ranges from 5 to 90 days. The symptoms and course resemble those of acute viral hepatitis, with prominent alanine aminotransferase elevations (increased by a factor of 5 to 50), whereas alkaline phosphatase levels are only modestly increased (Fig. 1B). Liver histologic studies show changes suggestive of acute viral hepatitis, the major disorder in the differential diagnosis, but eosinophils may be prominent. The rate of death from icteric hepatocellular injury due to medications is high, usually 10% or higher, a feature first stressed by the late Hyman J. Zimmerman, for which reason it is called Hy's law.<sup>1,34</sup> A key feature of Hy's law is jaundice with hepatocellular rather than cholestatic injury. Drug-induced idiosyncratic acute hepatocellular injury is an important cause of acute liver failure, accounting for 11 to 15% of cases in series from the United States and Europe.<sup>7,8</sup> Common causes of drug-induced idiosyncratic acute hepatocellular injury are isoniazid, nitrofurantoin, and diclofenac.<sup>13,16,33,35</sup>

Chronic hepatitis is an uncommon form of drug-induced liver injury; the chronicity occurs if the agent is continued and typically resolves slowly once the agent has been stopped. Many agents that cause acute hepatocellular injury can also cause a chronic hepatocellular pattern.<sup>1,35</sup> The injury arises after months or years of exposure. Autoantibodies are frequently present, and the differential diagnosis often focuses on ruling out spontaneous autoimmune hepatitis. Common causes of drug-induced, autoimmune-like chronic liver injury are nitrofurantoin, minocycline, hydralazine, methyldopa, statins, and fenofibrate.<sup>16,35-38</sup> Glucocorticoids, which are frequent-

ly used to manage chronic hepatitis (starting dose, 20 to 60 mg of prednisone or its equivalent daily), may alleviate symptoms and speed recovery, but the injury will often resolve without intervention. If prednisone is used, the dose and duration should be kept to a minimum. Monitoring for evidence of relapse should be performed for at least 6 months after the withdrawal of glucocorticoids. Ultimately, spontaneous autoimmune hepatitis is best ruled out by evidence of resolution of the liver injury after withdrawal of the medication and, if glucocorticoids are used, by the absence of relapse when they are discontinued.<sup>36</sup>

Cholestatic hepatitis is characterized by prominent symptoms of pruritus and jaundice accompanied by moderate-to-marked elevations in alkaline phosphatase levels (Fig. 1C). Drug-induced cholestatic liver injury is usually self-limited, and although often protracted, it ultimately resolves.<sup>13,39</sup> Liver histologic studies show bile duct injury and cholestasis in small bile canaliculi.<sup>40</sup> Exceptions to the usual benign course occur when there is bile duct loss, which is associated with delayed resolution of jaundice and elevated enzyme levels.<sup>41</sup> Some cases evolve into vanishing bile duct syndrome, with prolonged jaundice, liver failure, need for liver transplantation, or death. Common causes of drug-induced cholestatic hepatitis are amoxicillin-clavulanate, cephalosporins, terbinafine, azathioprine, and temozolomide.<sup>17,38,42-44</sup>

Drug-induced mixed hepatitis is caused by many agents, some of which also cause hepatocellular or cholestatic hepatitis.<sup>13,33</sup> The mixed forms of drug-induced liver injury tend to have the most benign outcomes, rarely leading to liver failure. Common causes of drug-induced mixed hepatitis include the fluoroquinolone and macrolide antibiotics, phenytoin, and sulfonamides.<sup>13,45,46</sup>

All forms of idiosyncratic drug-induced hepatitis can be accompanied by immunoallergic features, such as rash, fever, and eosinophilia — signs of drug hypersensitivity.<sup>13,33,47</sup> More extreme examples include drug reaction with eosinophilia and systemic symptoms (DRESS) syndrome, toxic epidermal necrolysis, and the Stevens-Johnson syndrome.<sup>48,49</sup> Prominent causes of idiosyncratic drug-induced hepatitis with immunoallergic features include allopurinol, carbamazepine, phenytoin, sulfonamides, and macrolide antibiotics.<sup>46-49</sup> Immunoallergic hepatitis is more common among black Americans than among non-Hispanic white Americans.<sup>50</sup>

Bland cholestasis represents a distinctive phenotype of drug-induced liver injury, characterized by marked and prolonged jaundice with pruritus. In women, bland cholestasis is typically caused by estrogens or oral contraceptives,<sup>51</sup> and in men it is typically caused by anabolic steroids, usually obtained illicitly for bodybuilding or improving athletic performance.<sup>52</sup> Jaundice and pruritus arise within 30 to 90 days, and elevations in enzyme levels are minimal or modest, despite marked and prolonged jaundice<sup>18,52</sup> (Fig. 1D). Liver biopsy shows bland cholestasis with scant inflammation and hepatocellular necrosis. The cholestasis can be prolonged, but the injury is almost always self-limited and deaths are rare. The pathogenesis remains unclear.

#### INDIRECT HEPATOTOXICITY

Indirect drug-induced liver injury results from the medication's actions rather than from its inherent hepatotoxic effects or immunogenicity; the injury represents induction or exacerbation of a liver disease. The phenotypes are those of the underlying disease or predisposition. Fatty liver disease can be an indirect effect of drugs that cause weight gain (risperidone and haloperidol)<sup>53</sup> or that alter triglyceride disposition (lomitapide)<sup>54</sup> or insulin sensitivity (glucocorticoids). Acute hepatitis can be the indirect effect of anticancer chemotherapeutic agents that cause a reactivation of hepatitis B<sup>55</sup> or of antiretroviral agents that cause immune reconstitution and exacerbation of hepatitis C.<sup>56</sup> An increasingly common form of indirect injury is immune-mediated liver injury due to various immunomodulatory agents,<sup>57-59</sup> tumor necrosis factor antagonists,<sup>60</sup> and most dramatically, antineoplastic checkpoint inhibitors.<sup>61,62</sup> Many of these agents are monoclonal antibodies and are thus unlikely to cause direct or idiosyncratic liver injury. Hepatocellular or mixed hepatitis with immune features usually arises within 2 to 12 weeks after the start of therapy (or after one to three courses) and is often detected during routine monitoring at the time of each infusion. Many cases are anicteric and asymptomatic, but without intervention, the hepatitis can worsen and become life-threatening. Therapy with glucocorticoids is usually recommended.<sup>62</sup> If the injury resolves promptly, the agent can be restarted or another agent can be substituted (infliximab can be switched to etanercept, or ipilimumab to nivolumab).

Indirect liver injury is a new and not completely accepted category of hepatotoxicity. Nevertheless, the clinical features are distinct (Table 1). Indirect injury is much more frequent than idiosyncratic forms and is a common reaction to a whole class of medications (e.g., tumor necrosis factor antagonists and checkpoint inhibitors) rather than a rare and idiosyncratic reaction to a random, specific agent (e.g., nitrofurantoin or atorvastatin). Indirect drug-induced liver injury represents an expanded concept of hepatotoxicity and provides insights into liver conditions that are worsened (e.g., the types of immunomodulation that cause reactivation of hepatitis B) or into predispositions to liver conditions. There are plausible explanations for the pathogenesis of indirect injury, and in most instances, this type of drug-induced liver injury can be prevented or treated.

#### CURRENT MAJOR CAUSES OF DRUG-INDUCED LIVER INJURY

The current major causes of clinically apparent liver injury due to prescription drugs are shown in Table 3.<sup>13</sup> These data are based on more than 1000 cases of suspected idiosyncratic drug-induced liver injury seen at five to eight medical centers across the United States between 2004 and 2013. All cases were formally adjudicated, and the implicated agent was classified as the definite, highly likely, or probable cause. The most commonly implicated agents were amoxicillin-clavulanate, isoniazid, nitrofurantoin, trimethoprim-sulfamethoxazole, and minocycline. These medications might be the most common causes of idiosyncratic drug-induced liver injury, but liver injury in persons taking these drugs is rare. Inclusion in the top 25 implicated agents reflects not just the hepatotoxicity potential but also how commonly the drugs are used and the duration of treatment, which can range from a single intravenous infusion (cefazolin),<sup>17</sup> to a 3-to-14-day course (oral antibiotics), to a year or more of therapy (nitrofurantoin, minocycline, and atorvastatin).<sup>13,37</sup> The actual incidence of idiosyncratic liver injury from specific drugs is difficult to define; estimates include 1 case per 1000 exposures (isoniazid), 1 per 2500 (amoxicillin-clavulanate), 1 per 10,000 (diclofenac), 1 per 20,000 (atorvastatin), and 1 per 50,000 or more (most drugs).<sup>5,12</sup> Host and environmental factors may affect the risk, but risk factors are not well de-

**Table 3. Most Frequent Causes of Idiosyncratic Prescription Drug–Induced Liver Injury.\***

Rank	Agent	Year of FDA Approval	No. (%)†	Major Phenotypes
1	Amoxicillin–clavulanate	1984	91 (10.1)	Cholestatic or mixed hepatitis
2	Isoniazid	1952	48 (5.3)	Acute hepatocellular hepatitis
3	Nitrofurantoin	1953	42 (4.7)	Acute or chronic hepatocellular hepatitis
4	TMP-SMZ	1973	31 (3.4)	Mixed hepatitis
5	Minocycline	1971	28 (3.1)	Acute or chronic hepatocellular hepatitis
6	Cefazolin	1973	20 (2.2)	Cholestatic hepatitis
7	Azithromycin	1991	18 (2.0)	Hepatocellular, mixed, or cholestatic hepatitis
8	Ciprofloxacin	1987	16 (1.8)	Hepatocellular, mixed, or cholestatic hepatitis
9	Levofloxacin	1996	13 (1.4)	Hepatocellular, mixed, or cholestatic hepatitis
10	Diclofenac	1988	12 (1.3)	Acute or chronic hepatocellular hepatitis
11	Phenytoin	1946	12 (1.3)	Hepatocellular or mixed hepatitis
12	Methyldopa	1962	11 (1.2)	Hepatocellular or mixed hepatitis
13	Azathioprine	1968	10 (1.1)	Cholestatic hepatitis

\* Data are from Chalasani et al.<sup>13</sup> The listed agents are those most frequently implicated in a total of 1257 cases of drug-induced liver injury reported between 2004 and 2013; agents were classified as definite, highly likely, or probable causes (in 899 cases). Agents that ranked from 14th to 25th in frequency were hydralazine, lamotrigine, and mercaptopurine (9 cases each); atorvastatin and moxifloxacin (8 cases each); and allopurinol, amoxicillin, duloxetine, rosuvastatin, telithromycin, terbinafine, and valproic acid (7 cases each). FDA denotes Food and Drug Administration.

† The percentages have been calculated on the basis of a total of 899 cases of drug-induced liver injury.

finer and are probably specific to the agent, such as male sex and older age for amoxicillin–clavulanate,<sup>39</sup> alcoholism for isoniazid,<sup>12</sup> and African ancestry for phenytoin, allopurinol, and trimethoprim–sulfamethoxazole.<sup>48,50</sup> Furthermore, there is little evidence that particular combinations of agents are more likely to lead to idiosyncratic hepatic injury, although combinations of hepatotoxins are fairly clear risk factors for direct injury.

A striking finding is that 9 of the top 10 causes of drug-induced liver injury are antimicrobial agents, largely antibiotics. In addition, most of the drugs have been in widespread use for decades. Among the 25 most commonly implicated agents, only 3 were introduced after 2000 (rosuvastatin [2003], duloxetine [2004], and telithromycin [2004]). The reasons that more recently approved drugs are less likely to be implicated in liver injury are not clear but may reflect improvements in drug design, preclinical screening for toxic effects, and a focus on agents with better safety profiles (those that are given in lower doses, are less likely to affect hepatic metabolism, are less lipophilic, and are less likely to interact with other drugs).<sup>2,63,64</sup> Another possible reason is the increased scrutiny and

criteria for proof of safety required by the Food and Drug Administration.<sup>34,65</sup>

Although recently approved agents may have fewer hepatotoxic effects, many are still of concern. Of note are the kinase and other targeted enzyme inhibitors, more than 50 of which have been introduced in the past two decades.<sup>12</sup> Most are antineoplastic agents that cause transient elevations in serum enzyme levels in a sizable proportion of patients and more rarely cause icteric, clinically apparent liver injury (e.g., imatinib, nilotinib, bortezomib, pazopanib, and ribociclib).<sup>60</sup> Also notable are monoclonal antibodies, more than 70 of which are now available. Although these agents are frequently used for cancer chemotherapy, their use has expanded to encompass the treatment of nonmalignant conditions such as autoimmune diseases, migraines, and hypercholesterolemia, as well as management after organ transplantation. Most monoclonal antibodies do not cause liver injury, the exception being those with immunomodulatory actions.

#### HERBAL AND DIETARY SUPPLEMENTS

The role of herbal and dietary supplements in causing acute liver injury is a growing and per-

plexing problem. In studies from the United States, the proportions of cases of liver injury caused by herbal or dietary supplements increased from 7 to 9% in 2004–2007 to 19 to 20% in 2010–2014.<sup>66,67</sup> This change probably reflects the increasing use of herbal products and dietary supplements, as well as the lack of rigorous regulatory oversight in the preparation and marketing of these products. The specific products implicated are generally not single herbs (aloe vera, saw palmetto, or black cohosh) or single nutritional substances (creatine, omega fatty acids, or vitamins) but rather are typically multiple-ingredient dietary supplements marketed for weight loss, bodybuilding, or improvements in sexual function, general well-being, or mental acuity.<sup>67</sup> These products often have 5 to 20 ingredients, including vitamins, minerals, proteins, and herbs or botanicals of uncertain quality and concentration, often referred to as a “proprietary blend.” The specific chemical component (or components) responsible for the liver injury is rarely obvious. Most multiple-ingredient dietary supplements have commercial names, which are linked to no more than one or two cases of liver injury. Some, however, have been implicated in outbreaks (e.g., Hydroxycut and OxyELITE Pro). Once a popular proprietary supplement is implicated in liver injury, the manufacturer may alter the ingredients and continue to market the product under the same name.

Strikingly, the clinical phenotype of liver injury in most cases associated with herbal and dietary supplements is acute hepatocellular hepatitis, which is often severe, with a high rate of fulminant hepatic failure and need for liver transplantation.<sup>66</sup> Commonly implicated components are green tea extracts (*Camellia sinensis*). The suspected active molecular constituents are catechins, which at high doses cause liver injury in animal models.<sup>66–68</sup> The concentrations of green tea in the animal models, however, are much higher than those in commercial supplements implicated in causing injury in humans.<sup>69</sup> In a placebo-controlled trial of green tea extract for the prevention of breast cancer, elevations in serum alanine aminotransferase levels occurred in 6.7% of recipients (36 of 538), as compared with 0.7% of controls (4 of 537).<sup>70</sup> The abnormalities were asymptomatic and resolved promptly with discontinuation of the supplement but recurred rapidly on readministration, suggesting that the injury was idiosyncratic and probably immune-mediated.

---

## PATHOGENESIS

---

The pathogenesis of direct and indirect hepatotoxicity is reasonably well understood, whereas that of idiosyncratic injury is not. Genomewide association studies of large numbers of idiosyncratic cases have identified several genetic associations, most within the major histocompatibility complex (MHC) region and linked to HLA class I and II alleles. In general, the HLA associations were to uncommon alleles and were specific to selected agents, such as HLA-B\*57:01 for flucloxacillin,<sup>71</sup> HLA-A\*02:01 and HLA-DRB1\*15:01 for amoxicillin–clavulanate,<sup>72</sup> and HLA-A\*33:01 for fenofibrate and terbinafine.<sup>38,42</sup> These associations were not reliable enough to warrant screening for HLA alleles in selecting medications, but they suggest an immunologic pathogenesis. This hypothesis is supported by the observation that implicated drugs or their metabolites bind to the active T-cell receptor groove dictated by the HLA association.<sup>73</sup>

More recently, genomewide association studies have identified a risk allele for idiosyncratic drug-induced liver injury outside the HLA region that is linked to a missense mutation in an immunomodulatory gene encoding PTPN22,<sup>74</sup> a protein tyrosine phosphatase that acts by down-regulating T-cell receptor signaling.<sup>75</sup> The same missense mutation (c.C1858T, p.R620W) has also been linked to an increased risk of autoimmune diseases. This allele appears to be linked to multiple forms of idiosyncratic drug-induced liver injury.

An attractive hypothesis is that idiosyncratic drug-induced liver injury is due to a perfect storm of events, each of which is required for full expression of the injury. The production of an abnormal metabolite of the drug by the liver is followed by mild liver-cell injury and then by an immunologic response to the metabolite presented on the injured hepatocyte surface to a specific HLA-restricted T-cell receptor.<sup>3,14,73</sup> Without adaptation, the immune recognition triggers further T-cell activation, cytokine release, and hepatocyte injury. This hypothesis may ultimately help to improve the identification of safer drugs in development.

---

## CONCLUSIONS

---

Drug-induced liver injury is an uncommon but clinically important form of liver disease, its frequency driven by how often drugs are taken and



the likelihood that they cause injury. The multiple types and phenotypes of injury vary according to the agent, presenting a diagnostic challenge. Recognizing phenotypes of drug-induced liver injury is helpful in establishing the diagnosis, identifying the responsible agent, and providing insights into pathogenesis. A better understanding of the pathogenesis of drug-induced

liver injury should allow for better diagnostics and, ultimately, improved approaches to prevention and treatment.

No potential conflict of interest relevant to this article was reported.

Disclosure forms provided by the authors are available with the full text of this article at NEJM.org.

We thank Drs. Paul Watkins and James Knoben for their advice and insights.

## REFERENCES

- Zimmerman HJ. Hepatotoxicity: the adverse effects of drugs and other chemicals on the liver. 2nd ed. Philadelphia: Lippincott Williams & Wilkins, 1999.
- Navarro VJ, Senior JR. Drug-related hepatotoxicity. *N Engl J Med* 2006;354:731-9.
- Kullak-Ublick GA, Andrade RJ, Merz M, et al. Drug-induced liver injury: recent advances in diagnosis and risk assessment. *Gut* 2017;66:1154-64.
- Sgro C, Clinard F, Ouazir K, et al. Incidence of drug-induced hepatic injuries: a French population-based study. *Hepatology* 2002;36:451-5.
- Björnsson ES, Bergmann OM, Björnsson HK, Kvaran RB, Olafsson S. Incidence, presentation, and outcomes in patients with drug-induced liver injury in the general population of Iceland. *Gastroenterology* 2013;144:1419-25.
- Vuppalanchi R, Liangpunsakul S, Chalasani N. Etiology of new-onset jaundice: how often is it caused by idiosyncratic drug-induced liver injury in the United States? *Am J Gastroenterol* 2007;102:558-62.
- Reuben A, Koch DG, Lee WM. Drug-induced acute liver failure: results of a U.S. multicenter, prospective study. *Hepatology* 2010;52:2065-76.
- Wei G, Bergquist A, Broomé U, et al. Acute liver failure in Sweden: etiology and outcome. *J Intern Med* 2007;262:393-401.
- Danan G, Benichou C. Causality assessment of adverse reactions to drugs — I. A novel method based on the conclusions of international consensus meetings: application to drug-induced liver injuries. *J Clin Epidemiol* 1993;46:1323-30.
- Rockey DC, Seeff LB, Rochon J, et al. Causality assessment in drug-induced liver injury using a structured expert opinion process: comparison to the Roussel-Uclaf causality assessment method. *Hepatology* 2010;51:2117-26.
- Björnsson ES, Hoofnagle JH. Categorization of drugs implicated in causing liver injury: critical assessment based on published case reports. *Hepatology* 2016;63:590-603.
- LiverTox: clinical and research information on drug-induced liver injury. Bethesda, MD: National Institutes of Health (<https://www.LiverTox.nih.gov>).
- Chalasani N, Bonkovsky HL, Fontana R, et al. Features and outcomes of 889 patients with drug-induced liver injury: the DILIN Prospective Study. *Gastroenterology* 2015;148(7):1340-52.e7.
- Watkins PB. Idiosyncratic liver injury: challenges and approaches. *Toxicol Pathol* 2005;33:1-5.
- Pye M, Northcote RJ, Cobbe SM. Acute hepatitis after parenteral amiodarone administration. *Br Heart J* 1988;59:690-1.
- Schmeltzer PA, Kosinski AS, Kleiner DE, et al. Liver injury from nonsteroidal anti-inflammatory drugs in the United States. *Liver Int* 2016;36:603-9.
- Alqahtani SA, Kleiner DE, Ghabril M, Gu J, Hoofnagle JH, Rockey DC. Identification and characterization of cefazolin-induced liver injury. *Clin Gastroenterol Hepatol* 2015;13(7):1328-1336.e2.
- Stolz A, Navarro V, Hayashi PH, et al. Severe and protracted cholestasis in 44 young men taking bodybuilding supplements: assessment of genetic, clinical and chemical risk factors. *Aliment Pharmacol Ther* 2019;49:1195-204.
- Larson AM, Polson J, Fontana RJ, et al. Acetaminophen-induced acute liver failure: results of a United States multicenter, prospective study. *Hepatology* 2005;42:1364-72.
- Dalton TA, Berry RS. Hepatotoxicity associated with sustained-release niacin. *Am J Med* 1992;93:102-4.
- McDonald GB. Hepatobiliary complications of hematopoietic cell transplantation, 40 years on. *Hepatology* 2010;51:1450-60.
- DeLeve LD, Shulman HM, McDonald GB. Toxic injury to hepatic sinusoids: sinusoidal obstruction syndrome (veno-occlusive disease). *Semin Liver Dis* 2002;22:27-42.
- Battipaglia G, Labopin M, Candoni A, et al. Risk of sinusoidal obstruction syndrome in allogeneic stem cell transplantation after prior gemtuzumab ozogamicin treatment: a retrospective study from the Acute Leukemia Working Party of the EBMT. *Bone Marrow Transplant* 2017;52:592-9.
- Richardson PG, Riches ML, Kernan NA, et al. Phase 3 trial of defibrotide for the treatment of severe veno-occlusive disease and multi-organ failure. *Blood* 2016;127:1656-65.
- Suárez Ferrer C, Llop Herrera E, Calvo Moya M, et al. Idiopathic portal hypertension regarding thiopurine treatment in patients with inflammatory bowel disease. *Rev Esp Enferm Dig* 2016;108:79-83.
- Cotte L, Bénet T, Billioud C, et al. The role of nucleoside and nucleotide analogues in nodular regenerative hyperplasia in HIV-infected patients: a case control study. *J Hepatol* 2011;54:489-96.
- Morris-Stiff G, White AD, Gomez D, et al. Nodular regenerative hyperplasia (NRH) complicating oxaliplatin chemotherapy in patients undergoing resection of colorectal liver metastases. *Eur J Surg Oncol* 2014;40:1016-20.
- McKenzie R, Fried MW, Sallie R, et al. Hepatic failure and lactic acidosis due to fialuridine (FIAU), an investigational nucleoside analogue for chronic hepatitis B. *N Engl J Med* 1995;333:1099-105.
- Wei C-M, Chen H-L, Lee P-I, Chen C-M, Ma C-Y, Hwu W-L. Reye's syndrome developing in an infant on treatment of Kawasaki syndrome. *J Paediatr Child Health* 2005;41:303-4.
- Peters RL, Edmondson HA, Mikkelsen WP, Tatter D. Tetracycline-induced fatty liver in nonpregnant patients: a report of six cases. *Am J Surg* 1967;113:622-32.
- Su E, Crowley K, Carcillo JA, Michaels MG. Linezolid and lactic acidosis: a role for lactate monitoring with long-term linezolid use in children. *Pediatr Infect Dis J* 2011;30:804-6.
- Dragovic G, Jevtovic D. The role of nucleoside reverse transcriptase inhibitors usage in the incidence of hyperlactatemia and lactic acidosis in HIV/AIDS patients. *Biomed Pharmacother* 2012;66:308-11.
- Andrade RJ, Lucena MI, Fernández MC, et al. Drug-induced liver injury: an analysis of 461 incidences submitted to the Spanish registry over a 10-year period. *Gastroenterology* 2005;129:512-21.
- Temple R. Hy's law: predicting serious hepatotoxicity. *Pharmacoepidemiol Drug Saf* 2006;15:241-3.
- de Boer YS, Kosinski AS, Urban TJ, et al. Features of autoimmune hepatitis in patients with drug-induced liver injury. *Clin Gastroenterol Hepatol* 2017;15(1):103-112.e2.

36. Björnsson E, Talwalkar J, Treeprasert-suk S, et al. Drug-induced autoimmune hepatitis: clinical characteristics and prognosis. *Hepatology* 2010;51:2040-8.
37. Russo MW, Hoofnagle JH, Gu J, et al. Spectrum of statin hepatotoxicity: experience of the Drug-Induced Liver Injury Network. *Hepatology* 2014;60:679-86.
38. Ahmad J, Odin JA, Hayashi PH, et al. Identification and characterization of fenofibrate-induced liver injury. *Dig Dis Sci* 2017;62:3596-604.
39. deLemos AS, Ghabril M, Rockey DC, et al. Amoxicillin-clavulanate-induced liver injury. *Dig Dis Sci* 2016;61:2406-16.
40. Kleiner DE, Chalasani NP, Lee WM, et al. Hepatic histological findings in suspected drug-induced liver injury: systematic evaluation and clinical associations. *Hepatology* 2014;59:661-70.
41. Bonkovsky HL, Kleiner DE, Gu J, et al. Clinical presentations and outcomes of bile duct loss caused by drugs and herbal and dietary supplements. *Hepatology* 2017; 65:1267-77.
42. Fontana RJ, Cirulli ET, Gu J, et al. The role of HLA-A\*33:01 in patients with cholestatic hepatitis attributed to terbinafine. *J Hepatol* 2018;69:1317-25.
43. Björnsson ES, Gu J, Kleiner DE, Chalasani N, Hayashi PH, Hoofnagle JH. Azathioprine and 6-mercaptopurine-induced liver injury: clinical features and outcomes. *J Clin Gastroenterol* 2017;51:63-9.
44. Grant LM, Kleiner DE, Conjeevaram HS, Vuppalanchi R, Lee WM. Clinical and histological features of idiosyncratic acute liver injury caused by temozolomide. *Dig Dis Sci* 2013;58:1415-21.
45. Orman ES, Conjeevaram HS, Vuppalanchi R, et al. Clinical and histopathologic features of fluoroquinolone-induced liver injury. *Clin Gastroenterol Hepatol* 2011;9(6):517-523.e3.
46. Martinez MA, Vuppalanchi R, Fontana RJ, et al. Clinical and histologic features of azithromycin-induced liver injury. *Clin Gastroenterol Hepatol* 2015;13(2): 369-376.e3.
47. Devarbhavi H, Karanth D, Prasanna KS, Adarsh CK, Patil M. Drug-induced liver injury with hypersensitivity features has a better outcome: a single-center experience of 39 children and adolescents. *Hepatology* 2011;54:1344-50.
48. Knowles SR, Dewhurst N, Shear NH. Anticonvulsant hypersensitivity syndrome: an update. *Expert Opin Drug Saf* 2012;11: 767-78.
49. Devarbhavi H, Raj S, Aradya VH, et al. Drug-induced liver injury associated with Stevens-Johnson syndrome/toxic epidermal necrolysis: patient characteristics, causes, and outcome in 36 cases. *Hepatology* 2016;63:993-9.
50. Chalasani N, Reddy KR, Fontana RJ, et al. Idiosyncratic drug induced liver injury in African-Americans is associated with greater morbidity and mortality compared to Caucasians. *Am J Gastroenterol* 2017;112:1382-8.
51. Pauli-Magnus C, Meier PJ, Stieger B. Genetic determinants of drug-induced cholestasis and intrahepatic cholestasis of pregnancy. *Semin Liver Dis* 2010;30: 147-59.
52. Robles-Diaz M, Gonzalez-Jimenez A, Medina-Caliz I, et al. Distinct phenotype of hepatotoxicity associated with illicit use of anabolic androgenic steroids. *Aliment Pharmacol Ther* 2015;41:116-25.
53. Kumra S, Herion D, Jacobsen LK, Briguglia C, Grothe D. Case study: risperidone-induced hepatotoxicity in pediatric patients. *J Am Acad Child Adolesc Psychiatry* 1997;36:701-5.
54. Sacks FM, Stanesa M, Hegele RA. Severe hypertriglyceridemia with pancreatitis: thirteen years' treatment with lomitapide. *JAMA Intern Med* 2014;174:443-7.
55. Di Bisceglie AM, Lok AS, Martin P, Terrault N, Perrillo RP, Hoofnagle JH. Recent US Food and Drug Administration warnings on hepatitis B reactivation with immune-suppressing and anticancer drugs: just the tip of the iceberg? *Hepatology* 2015;61:703-11.
56. Kim HN, Harrington RD, Shuhart MC, et al. Hepatitis C virus activation in HIV-infected patients initiating highly active antiretroviral therapy. *AIDS Patient Care STDS* 2007;21:718-23.
57. Nociti V, Biolato M, De Fino C, et al. Liver injury after pulsed methylprednisolone therapy in multiple sclerosis patients. *Brain Behav* 2018;8(6):e00968.
58. Aliberti S, Grignani G, Allione P, et al. An acute hepatitis resembling autoimmune hepatitis occurring during imatinib therapy in a gastrointestinal stromal tumor patient. *Am J Clin Oncol* 2009;32:640-1.
59. Fontana RJ, Hayashi P, Bonkovsky HL, et al. Presentation and outcomes with clinically apparent interferon beta hepatotoxicity. *Dig Dis Sci* 2013;58:1766-75.
60. Ghabril M, Bonkovsky HL, Kum C, et al. Liver injury from tumor necrosis factor- $\alpha$  antagonists: analysis of thirty-four cases. *Clin Gastroenterol Hepatol* 2013; 11(5):558-564.e3.
61. Kleiner DE, Berman D. Pathologic changes in ipilimumab-related hepatitis in patients with metastatic melanoma. *Dig Dis Sci* 2012;57:2233-40.
62. Huffman BM, Kottschade LA, Kamath PS, Markovic SN. Hepatotoxicity after immune checkpoint inhibitor therapy in melanoma: natural progression and management. *Am J Clin Oncol* 2018;41:760-5.
63. Lammert C, Einarsson S, Saha C, Niklasson A, Björnsson E, Chalasani N. Relationship between daily dose of oral medications and idiosyncratic drug-induced liver injury: search for signals. *Hepatology* 2008;47:2003-9.
64. Regev A. Drug-induced liver injury and drug development: industry perspective. *Semin Liver Dis* 2014;34:227-39.
65. Avigan MI. DILI and drug development: a regulatory perspective. *Semin Liver Dis* 2014;34:215-26.
66. Navarro VJ, Barnhart H, Bonkovsky HL, et al. Liver injury from herbs and dietary supplements in the U.S. Drug-Induced Liver Injury Network. *Hepatology* 2014;60:1399-408.
67. Navarro VJ, Khan I, Björnsson E, Seeff LB, Serrano J, Hoofnagle JH. Liver injury from herbal and dietary supplements. *Hepatology* 2017;65:363-73.
68. Bonkovsky HL. Hepatotoxicity associated with supplements containing Chinese green tea (*Camellia sinensis*). *Ann Intern Med* 2006;144:68-71.
69. Zheng EX, Rossi S, Fontana RJ, et al. Risk of liver injury associated with green tea extract in SLIMQUICK® weight loss products: results from the DILIN prospective study. *Drug Saf* 2016;39:749-54.
70. Dostal AM, Samavat H, Bedell S, et al. The safety of green tea extract supplementation in postmenopausal women at risk for breast cancer: results of the Minnesota Green Tea Trial. *Food Chem Toxicol* 2015;83:26-35.
71. Daly AK, Donaldson PT, Bhatnagar P, et al. HLA-B\*5701 genotype is a major determinant of drug-induced liver injury due to flucloxacillin. *Nat Genet* 2009;41: 816-9.
72. Lucena MI, Molokhia M, Shen Y, et al. Susceptibility to amoxicillin-clavulanate-induced liver injury is influenced by multiple HLA class I and II alleles. *Gastroenterology* 2011;141:338-47.
73. Kim SH, Saide K, Farrell J, et al. Characterization of amoxicillin- and clavulanic acid-specific T cells in patients with amoxicillin-clavulanate-induced liver injury. *Hepatology* 2015;62:887-99.
74. Cirulli ET, Nicoletti P, Abramson K, et al. A missense variant in PTPN22 is a risk factor for drug-induced liver injury. *Gastroenterology* 2019;156(6):1707-1716.e2.
75. Stanford SM, Bottini N. PTPN22: the archetypal non-HLA autoimmunity gene. *Nat Rev Rheumatol* 2014;10:602-11.

Copyright © 2019 Massachusetts Medical Society.